

Dr. Dave Webster
Diagnostic Imaging
Health Sciences North
41 Ramsey Lake Road
Sudbury ON
P3E 5J1

March 19, 17

PET ACCESS PROGRAM
Cancer Care Ontario
620 University Avenue
Toronto, Ontario
Canada
M5G 2L7

RE:Patient ID 21337

Dear PET ACCESS PANEL

I would like to suggest that we are at a 'crossroads' in that we have an opportunity as physicians to demonstrate that we are all working together to do what is best for our patients in a truly 'patient focused system'. The only reason to take the unusual step of asking members of the PET ACCESS panel to answer patients questions and address their concerns is when the approach of the Panel seems at odds with the basis by which decisions her consulting physicians are expected to follow.

Let us consider the case of the woman who is identified as patient 21337.

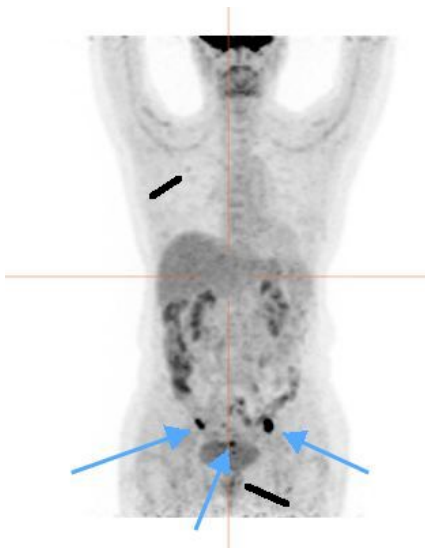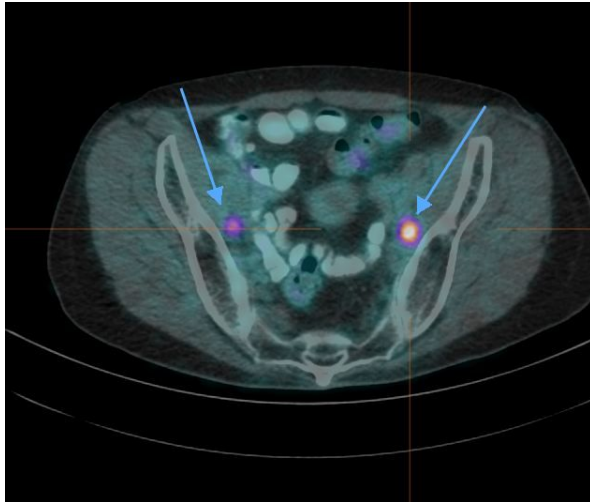
As you know, this unfortunate woman has cancer of the cervix. Her investigation with CT and MRI had raised the possibility of metastatic nodes on the left but was inconclusive. Thus when the patient's radiation therapy mapping was done, full radical treatment doses were directed to the cervical tumor areas, but not full dose to the left internal iliac chain.

What the post-treatment PET showed was that there was a prominent left internal iliac chain node with high SUV indicating as certain as we can be that there was persistent cancer. In addition there was uptake in several higher nodes, one at the level of the bifurcation of the aorta and even above this level. However the uptakes although concerning were not diagnostic and will need to be followed.

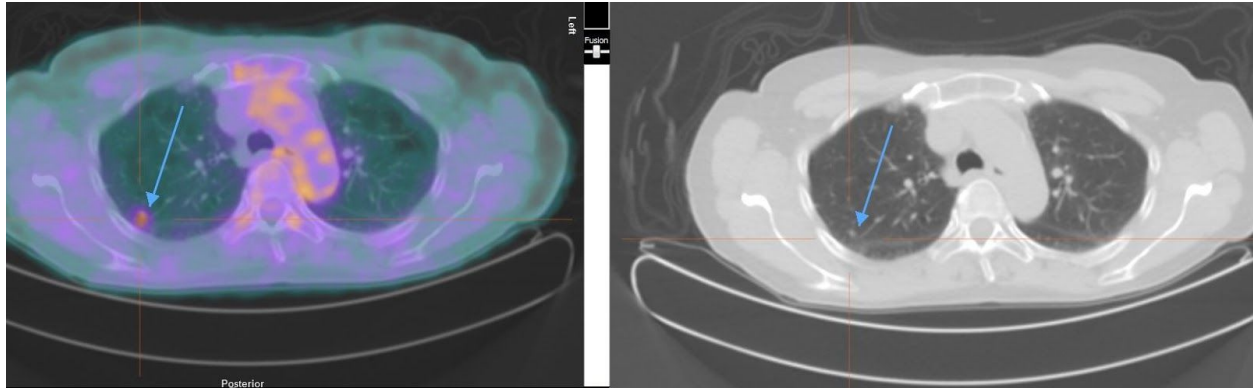
The PET also demonstrated that an absolutely normal size node in the right iliac chain was taking up high doses of FDG and therefore highly suspicious for active cancer. There was an incomplete response in cervical area including a focus in the uterus. However, as you know,

now that the patient has had radiation to her pelvis the options of now directing radical therapy doses to these areas are very limited.

As the Radiation Oncologist said in conversation: "If I had of had the PET I would have been able to direct her therapy more appropriately."



Further, the FDG PET/CT scan showed that she has three small nodules in her lungs in the size range of 5-6 mm. The SUV-max values were 1.5 and because of the small size these values would be underestimated due to partial volume effect. Therefore the fact that they are being visualized is not diagnostic but concerning.



Based on the PET in her pelvis, the patient's surgeons in Hamilton have decided that she is not a surgical candidate but does need follow-up imaging. Indeed, with the potential lung findings it would have meant that she may not have had to go through the pelvic radiation treatments with all the significant side-effects she suffered from.

The question is how she will be followed. They have recommended the 'standard' CT and MR follow-up. ***Yet, it is because of the inherent limitations of her CT and MR that she did not have ideal treatment from the very beginning.***

Therefore I would suggest that the way to best management subsequent decisions in this patient, which is the role of any imaging to be considered, is what will give the patient and her physician the best information about her current state of disease with minimum risks such as radiation exposure. The best available scientifically based evidence would support that this be with PET/CT exams.

The PET/CT, as demonstrated perfectly in this case, not only can we see the masses identified on the patient's diagnostic CT, but by adding the FDG component can determine in a semi-quantitative manner the behaviour of the indeterminate findings it identified, including uptake in areas that would not be reported on the CT or MR since they would be considered normal. I would hope you would agree, that this will provide the critical information the patient and her physician will need in order to direct her subsequent management, including issues surrounding her quality of life.

FDG PET on average upstages 30% of patients. Consider the findings in her lungs. She had not had any CT imaging of her chest since metastasis would not have been expected. PET/CT is routinely acquired from base of brain to mid-thigh, and as is demonstrated here, and picked up these unexpected findings needing to be followed appropriately.

CONCLUSIONS:

Therefore is the PET ACCESS Panel prepared to allow this woman to have her necessary follow-up with a PET/CT? If this is the case there would obviously be no need to answer any of the patients questions, since I would be happy to discuss the images and subsequent management with the patient and her physicians. In this case the approach to her case would be in keeping with the best available information using the standards of medical care that as her physicians we will be expected to use.

As you contemplate the directions PET ACCESS is going to take into the immediate future, consider the kind of information that is getting out to the public. There have now been numerous media pieces I would be happy to share with committee members, including my recent news Queen's Park news conference with Ms. France Gelinias the NDP Health Critic and Mr. Bill Walker, Conservative Critic for Long-Term Care. There will be much more media and maximal use of Social Media to make any and all documents, including this letter with relevant names removed, available not just to the patients I am dealing with but to the public so they can decide for themselves about what is happening in Ontario. A key time with upcoming elections.

<http://www.thesudburystar.com/2017/03/06/mobile-pet-no-brainer>

Regards

Dr. Dave Webster